

FILE

ROSS TECH 08/48
**Green Muscle
Disease**

Reducing the
Incidence in
Broiler Flocks

March 2008



Aviagen provides customers with detailed Product Performance Specifications, Management Manuals and Nutrition Specifications as the basis for managing their flocks. Successful production of day old chicks or grown broilers also depends on the understanding and attention to detail in the day-to-day management of stock. This document is produced by Aviagen's Technical Transfer Department as one of an ongoing series of Ross Techs. These give background information on various topics to provide an understanding of the principles which are essential to successful management of both breeders and broilers. Whilst the principles should have a broad relevance to most regions and production strategies, certain aspects may be directed to more specific situations.

About the Authors – Dr S.F. Bilgili and Dr Joseph Hess

Dr S.F. 'Sarge' Bilgili is Professor and Extension Scientist in the Department of Poultry Science at Auburn University, Alabama, USA. His current responsibilities include developing and implementing outreach and research programmes in the areas of broiler processing technology, slaughter and processing efficiency, broiler carcass quality and meat yield, food safety and animal welfare. He has authored or co-authored numerous articles in scientific and trade journals and serves on several industry and academic committees. He is currently Chairman of the National Chicken Council Animal Welfare Scientific Advisory Committee.



Dr Joseph Hess is an Extension Specialist and Associate Professor in the Poultry Science Department at Auburn University, Alabama, USA. His research focuses on practical aspects of management and nutrition in broilers and broiler breeders and he engages in practical research projects that can provide immediate feedback to the industry in terms of poultry performance, product quality or feed technology. He is a member of the Poultry Science Association, the Southern Poultry Science Society, the Alabama Poultry & Egg Association and works closely with the Alabama Feed & Grain Association.



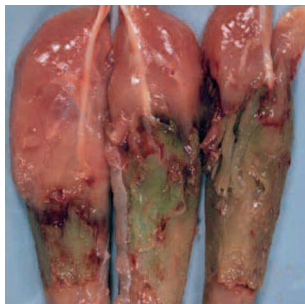Executive Summary

Green Muscle Disease (or Deep Pectoral Myopathy, DPM) is a degenerative disease of the minor pectoral muscles (i.e. the tenders), which is characterised by atrophy and necrosis. The condition arises when the muscle fibres become deficient in oxygen and is associated with sudden and excessive wing flap. The development of the disease can be split into three categories. Category 1 is the acute inflammatory lesion in which the deep pectoral muscle is very red and haemorrhagic. Category 2 describes the stage at which the lesion in the inner fillet becomes well defined and is sometimes circumscribed by a haemorrhagic ring. Category 3 describes the progressive degeneration and greening of damaged tissue. Although the incidence of DPM is increased in heavy broilers, it can occur at any age or weight and is dependent upon the management and husbandry systems employed. Identifying and eliminating the management issues which contribute to wing flapping and the development of the condition is key to reducing the incidence of DPM.

Introduction

Green Muscle Disease is a hidden problem in modern-day broiler chickens. Green Muscle Disease (or Oregon Disease) is a common name given to a degenerative muscle disease known as Deep Pectoral Myopathy (DPM). The condition is characterised by necrosis and atrophy of the tenders (i.e. supracoracoideus or minor pectoral muscles). The lesions often affect both tenders and vary in colour, progressing from a pinkish haemorrhagic appearance to a gray-greenish discolouration as illustrated in **Figure 1**.

Figure 1: Deep Pectoral Myopathy



DPM was first described in mature breeder turkeys and broiler breeders, but is being seen more in meat-type chickens, especially those selected for breast muscle development. The affected muscles are discarded during de-boning, resulting in saleable yield losses. However, the major issue with DPM is that if the birds are marketed as whole carcasses or parts, the problem is rarely detected during processing, resulting in consumer complaints and making the cause of the problem difficult to identify.

The condition is not associated with any infectious agent and therefore has no public health significance other than affecting the aesthetic appearance of the meat.

DPM is rarely detectable during processing if the birds are marketed as whole carcasses or parts.

Why Does DPM Target Broiler Breast Muscles?

- The pectoral muscles in avian species are associated with flight and the deep and superficial pectorals work in synergy, one to raise the wing and the other to lower it.
- The anatomy of these muscles is, however, intrinsically different in that the inner fillet has a tough outer sheath which is made up of dense fibrous tissue and is inelastic.
- The outer or major muscle is simply surrounded by loose connective tissue that moves easily over the muscle surface as the muscle profile changes.

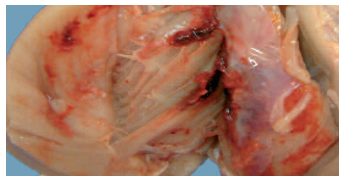
Contraction of the major pectoral muscles (the breast fillet) and the minor pectoral muscles (the tender) are responsible for the up- and down-strokes of the wings. During contraction, these muscles expand with increased blood supply (i.e. muscle pumping). The expansion of the minor pectoral muscle, by as much as 25% in volume, is problematic because this muscle is confined in a 'tight compartment', sandwiched between bone (the sternum) and the large breast fillet. The minor pectoral muscle is also encased in a rigid fibrous sheath which restricts increases in muscle volume. Therefore, when intramuscular pressure increases to levels above circulating blood pressure, the blood supply flowing into the muscle stops and, with continued muscle activity, oxygen deficiency rapidly develops and lack of oxygen (ischaemic necrosis) of the muscle fibres occurs. There is also an additive effect as the muscle pH falls. Typically, the middle third of the muscle is involved. In experimental studies, relatively short periods of wing flap are enough to induce these degenerative changes.

Recognition and Identification of the Development Stages in DPM

In response to complaints of DPM from the processing plant and/or customers, an investigation should be organised. This should include the identification of the category of DPM (fresh or old) at the processing plant. This information can then be correlated to husbandry management practices.

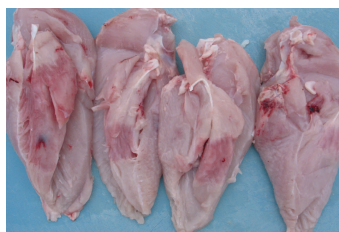Category 1: The acute inflammatory lesion in which the deep pectoral muscle is very red and haemorrhagic. Haemorrhages also appear on the fibrous sheath (**Figure 2**). There is an obvious suffusion of serous fluid in the area of the damage making it appear wet. This stage is likely to be associated with a handling event (e.g. catching) and will be present for about 48 hours.

Figure 2: Early Acute Pectoral Myopathy



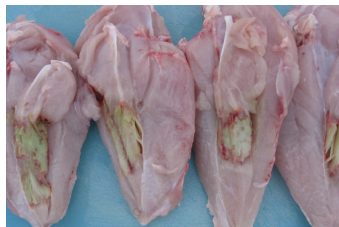Category 2: At this stage the lesion in the inner fillet has become well defined and is sometimes circumscribed by a haemorrhagic ring (**Figure 3**). The affected areas are pale pink to plumb coloured and there are clear changes consistent with early coagulative necrosis of the muscle, when the tissue texture becomes fibrous. This is sometimes described as 'fish flesh'. This stage will continue for a few days after the initial event or incident.

Figure 3: Pectoral Myopathy – Developing Lesions



Category 3: The progressive degeneration and greening of the damaged tissue (**Figure 4**). Often, only the middle part of the fillet is involved and the progressive greening is in parallel with the loss of cellular structure, so that a 'putty like' consistency develops within the lesion. This green, necrotic area will persist and through time will gradually reduce in size as it is reabsorbed, so that the symmetry of the breast is lost in some older birds. The green colour is produced by the breakdown of haemoglobin and myoglobin to bile salts.

Figure 4: Aged Pectoral Myopathy



Factors Affecting the Occurrence of DPM

The pectoral muscles make up nearly a quarter of the total liveweight in current-day meat chickens. Rearing broiler chickens to heavy market weights can increase the probability for occurrence of DPM. Incidence is dependant on management and husbandry systems and not simply bodyweight and birds at any age or weight can be affected.

DPM is associated with the following factors:

- Excessive wing flapping
- Heavy market bodyweight
- Sex: incidence can be higher in males compared to females
- High white meat yield
- Rapid growth rate

The desirable efficiency in growth and anatomy of today's broiler brings with it the possibility of DPM development.

Commercially raised broiler chickens are kept relatively comfortable and inactive during the growing period. Consequently, the pectoral muscles are not exercised enough to increase efficiency of the circulatory supply to the muscles and to allow the expansion of the surrounding fibrous sheath. It is doubtful that even a subtle amount of wing activity would help improve circulation or develop the sheath adequately.

Few, if any, processing plants actually track or document the incidence of DPM on a regular basis. Detection of DPM on whole carcasses and parts is extremely difficult as lesions are not visible during carcass inspection or sorting. As birds also exhibit no symptoms, finding affected live birds in a flock and treating them is not possible.

The key to avoiding the DPM lies with preventative management. Controlling the incidence of DPM hinges upon identifying and eliminating certain flock management issues that contribute to the development of the condition.

The key to reducing the incidence of DPM lies in management of the broiler flock and minimising wing flapping.

To avoid the occurrence of DPM, the following flock management guidelines (**Table 1**) are suggested as starting points to investigate and minimise any unnecessary wing activity.

Table 1: Flock Management Guidelines to Minimise Unnecessary Wing Activity

Do Not Stress or Frighten Birds	Limit Sudden and Excessive Wing Exercise	Control Overall Flock Flightiness
Do not allow other animals in or around the house.	Avoid excessive human activity in the house, especially if the birds are flighty.	Bird activity and flightiness increases with increasing natural day length.
Eliminate novel sounds (buzzing security lights, sudden use of noisy ventilation fans, tractor/generator operation in/near houses).	Avoid walking birds too fast, especially when migration barriers (nets, pipes or fences) are used; this may cause the birds to pile up.	Birds respond to increased light intensity with increased activity. Blue curtains may help calm the flocks in curtain-sided facilities.
Limit weighing or penning birds. Weigh birds in a bucket (or similar) instead of by legs.	Train personnel for gentle bird handling techniques during catching. Do not catch birds by their wings.	In environmentally controlled houses, avoid sudden and excessive increases in light intensity with dimmers - especially under low light intensity (<3 lux) conditions.
Avoid excitement induced by frequent thinning of flocks.	Keep birds comfortable during transport to the processing plant. Low crate stocking densities can cause problems. Prevent any unnecessary bird movements when crated.	Avoid extended periods (>3-4 hours) of feed and/or water withdrawal.
In tunnel ventilated houses use migration fences (approximately 30m (100 ft) apart).	Automatic catching systems can exacerbate wing flapping depending on the system used.	Intermittent lighting programmes can be a potential problem due to frequent bird stimulation.
	Minimise birds perching on swinging equipment such as feed tracks which allow birds to flap.	Ensure that stocking density, feeder and drinker space are adequate.
		A dawn to dusk type dimmer offers a gradual increase in lux.

Conclusion
Reducing DPM is a broiler management responsibility.



Every attempt has been made to ensure the accuracy and relevance of the information presented. However, Aviagen accepts no liability for the consequences of using the information for the management of chickens.

For further information on the management of Ross stock, please contact your local Technical Service Manager or the Technical Services Department.

Newbridge
Midlothian, EH28 8SZ
Scotland, UK

t. +44 (0) 131 333 1056
f. +44 (0) 131 333 3296
infoworldwide@aviagen.com

Cummings Research Park
5015 Bradford Drive
Huntsville, Alabama 35805, USA

t. +1 256 890 3800
f. +1 256 890 3919
info@aviagen.com